

Synthesis of Donor Type γ G-Globulin Following Thymus Transplantation in Hypo- γ -Globulinaemia with Severe Lymphocytopenia

MORTEN HARBOE, M.D., HELENE PANDE, M.D., PER BRANDTZAEG, D.D.S., M.S.,
KJELL J. TVETER, M.D. & PETER F. HJORT, M.D.

*University of Oslo, Institute for Experimental Medical Research (Chief, F. Kiil),
Ullevål Hospital, Oslo
and*

*Children's Hospital (Chief, L. Salomonsen), Histochemical Laboratory
(Chief, S. D. Schultz-Haudt), Institute of Pathological Anatomy (Chief, O. Torgersen),
and Section for Haematology, Medical Department A (Chief, P. F. Hjort),
University Hospital (Rikshospitalet), Oslo, Norway*

In an infant with hypo- γ -globulinaemia and severe lymphocytopenia thymus transplantation induced formation of a monoclonal γ G-globulin and a monoclonal γ M-globulin. The patient and his parents were Gm(-1), whereas the monoclonal γ G-globulin was Gm(1). The father of the thymus donor was Gm(1). We concluded that the monoclonal γ G-globulin was synthesized by cells originating from the thymus graft.

Antibody deficiency syndromes have only partly been separated into different nosological entities. One of these, the so-called 'Swiss form of hypo- γ -globulinaemia', is an invariably fatal disease characterized by extreme hypoplasia of lymphoid tissues, lymphocytopenia, and hypo- γ -globulinaemia. Increased tendency to infections, diarrhoea, and severe dystrophy dominate the clinical picture. The thymus is abnormal, and this genetically determined defect is probably the cause of the disease (Glanzmann & Riniker 1950, Tobler & Cottier 1958, Hitzig *et al.* 1958, Barandun *et al.* 1958, Good *et al.* 1963, Peterson *et al.* 1965). Thymus transplantation has therefore been pro-

The notation used for genetic factors of γ G-globulins was proposed by a WHO Scientific Group on 'Genes, Genotypes and Allotypes of Immunoglobulins' meeting in Geneva, June 1965. Bull. Wld Hlth Org. (1965) 33, 721-24.

The work was supported by grants from the Norwegian Council on Cardiovascular Disease, The Nansen Foundation, The Norwegian Research Council for Science and the Humanities, and Sev. Dahl's fund.

posed as a therapeutic measure (Rosen *et al.* 1962, Hitzig 1963, Peterson *et al.* 1965, Hitzig *et al.* 1965).

We report a patient with hypo- γ -globulinaemia and severe lymphocytopenia in whom thymus transplantation induced formation of a monoclonal γ M-globulin and a monoclonal γ G-globulin. Genetic markers indicated that the monoclonal γ G-globulin was synthesized by cells originating from the thymus graft.

CASE REPORT

P.E., a boy born March 20, 1965, was the second child of healthy, unrelated parents. The older sister was healthy, and no similar disease had been noted among the relatives. The sera of the parents contained normal amounts of γ G-, γ A-, and γ M-globulin.

He was born two weeks before term after a normal gestation. The birth weight was 3,260 g. A slight jaundice appeared after a few days and disappeared four weeks later. He was a weak suckling and was bottle-fed after a few weeks. At two weeks he developed a dry and non-productive cough, unrelated to feeding-times. The cough often ended in vomits. At six weeks he was wasted, weighing only 3,300 g. Fine rales were heard over the lungs, and a chest film showed multiple peribronchial infiltrations. He was admitted to a local hospital at seven weeks. It was noticed that his stools were paler, softer, and more frequent than normal. Leucocyte counts varied from 3,200 to 7,200 per μ l with 14–20 per cent eosinophilic granulocytes.

At eleven weeks he was transferred to the Children's Hospital, Rikshospitalet, Oslo. He was dystrophic with an extensive oral thrush and a pertussoid cough. The pulmonary findings were the same as before. The muscles were hypotonic and the abdomen somewhat protruding. No tonsils could be seen, and there were no palpable lymph nodes. The spleen and liver was not palpable.

Laboratory findings. Hb 14.8 g/100 ml. Red blood cells 4.7 million per μ l. Reticulocytes 0.2 per cent. The blood smear showed moderate anisocytosis with some macrocytosis; otherwise the red cells were normal. Leucocytes 4,800 per μ l with 11 per cent eosinophils, 8 per cent band formed neutrophils, 50 per cent polymorphonuclear neutrophils, 2 per cent lymphocytes, and 29 per cent monocytes. The granulocytes were normal, except for some toxic granulation. The leucocyte alkaline phosphatase score was 194. Blood platelets 65,000 per μ l. No plasma cells were found in buffy coat preparations. The important finding was a severe lymphocytopenia (96 lymphocytes per μ l).

The bone marrow (Table I) was cellular. The erythropoiesis was normal with occasional megaloblastoid cells. The myelopoiesis and the megakaryocytes appeared normal. The number of reticulum cells and monocytes was increased. Normally appearing lymphocytes were seen, but not a single plasma cell was observed in three smears.

Serum protein concentration was 6.2 g/100 ml. On admission, routine paper electrophoresis indicated a γ -globulin concentration of 6 mg/ml, but a re-evaluation with correction for albumin adsorbed to the paper (Sommerfelt 1953) gave a value of only 2 mg/ml. The serum and sweat electrolytes were normal. Urea 27 mg/100 ml. Serum alkaline phosphatase activity 10.7 Bodansky units. The proconvertin prothrombin level was 29 per cent and rose to 60 per cent after vitamin K injections. The fasting blood sugar was low, 30–36 mg/100 ml. A glucose tolerance test gave a normal response. The stools showed signs of malabsorption with increased amounts of fat – 42 per cent increasing to 62 per cent fat in dry faecal mass. Trypsin was present in normal amounts.

TABLE I
Cellular composition of the bone marrow
 (500 cells counted)

	Patient	Normal (Glaser <i>et al.</i> 1950)
Myeloblasts	2.0 per cent	(1.5 - 2.5 per cent)
Promyelocytes	1.8 —	(1.4 - 2.2 —)
Myelocytes: Eosinophilic	1.8 —	(0.0 - 1.5 —)
— Neutrophilic	6.2 —	(15.5 -16.5 —)
Metamyelocytes and band- formed granulocytes	18.2 —	(21.5 -27.8 —)
Polymorphonuclear eosinophils	3.6 —	(0.0 - 1.75 —)
— basophils	0.2 —	(0.0 - 0.75 —)
— neutrophils	20.4 —	(6.0 - 8.0 —)
Lymphocytes	7.4 —	(24.0 -29.5 —)
Monocytes	4.6 —	(0.0 - 0.75 —)
Reticulum cells	6.8 —	(0.0 - 1.25 —)
Megakaryocytes	1.4 —	(0.02- 0.5 —)
Pronormoblasts	0.4 —	(0.62- 0.64 —)
Normoblasts	19.8 —	(15.5 -19.0 —)
Unclassifiable cells	5.4 —	
Plasma cells	0.0 —	(0.0 - 1.0 —)

Urine tests were negative for protein, blood and sugars; a paper chromatogram showed a normal amino acid pattern. The excretion of 17-ketosteroids and 17-hydroxycorticosteroids was normal. The *Toxoplasma* dye test was negative, as was also a search for *Haemophilus pertussis*, cytomegalic inclusion bodies, and other viruses. Coagulase positive staphylococci were cultivated from a throat swab, and the urine contained *Escherichia coli*. Both strains were sensitive to sulphonamides.

August 5, at 4½ months, serum was tested by immuno-electrophoresis. The γ G-globulin concentration was lower than normal; specific quantitation revealed 0.7 mg γ G-globulin/ml. γ A- and γ M-globulins were not detectable. A skin test with 1-chloro-2,4-dinitro-benzene was negative. The patient was of blood group A₁, but no iso-haemagglutinins were found on this or later examinations.

These findings established the diagnosis of hypo- γ -globulinaemia with severe lymphocytopenia.

Thymus transplantation. August 19, a 16 weeks-old, 17 cm long male foetus delivered by Caesarian section was available for thymus transplantation. It was transported in intact foetal membranes to our hospital. Regular heart contractions were seen when the chest was opened two hours later to remove the pea-sized thymus. The capsule was incised once, and the gland was implanted in the rectus abdominis muscle of the patient.

Clinical course and observations. He was dystrophic throughout the course of the disease (Figure 1) and did not gain weight. A survey of the clinical course is given in Figure 2.

At the time of thymus transplantation, the right groin was surgically explored for lymph nodes but none were found. Microscopic examination of serial sections from this tissue showed no lymphatic structures. About four weeks after transplantation a few lymph nodes could be palpated in the right supraclavicular region, and one grew to the size of a pea.

Three days before transplantation, intravenous fluid therapy was needed because of dehydration. A metal needle was introduced into a scalp vein and remained there for

seven days without any of the reactions which usually lead to thrombosis within 1-2 days. Four days after removal a slight rubor appeared at the injection site. It increased to a pustule in the course of 4-5 days and finally dried up.

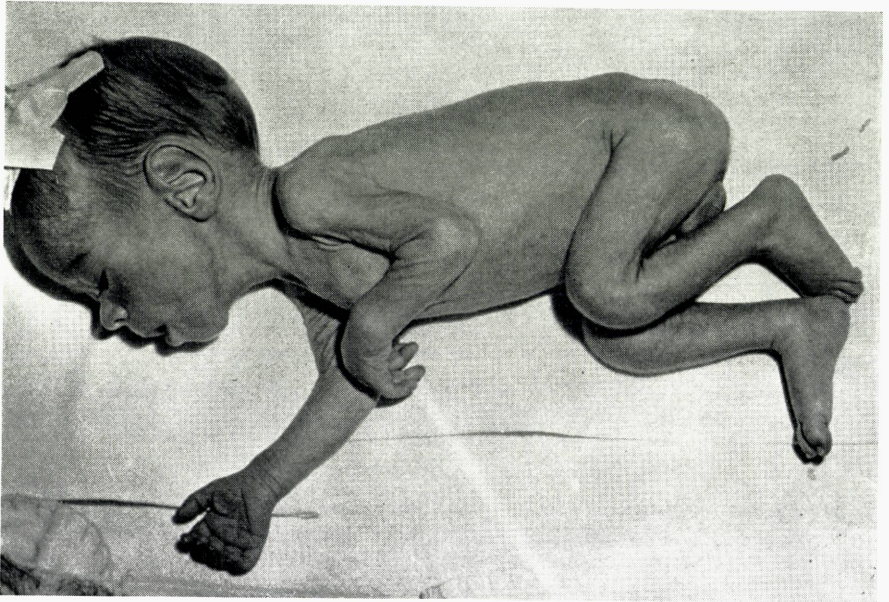


Figure 1. Appearance of a five-month-old boy with hypo- γ -globulinaemia and severe lymphocytopenia. Note extreme dystrophy.

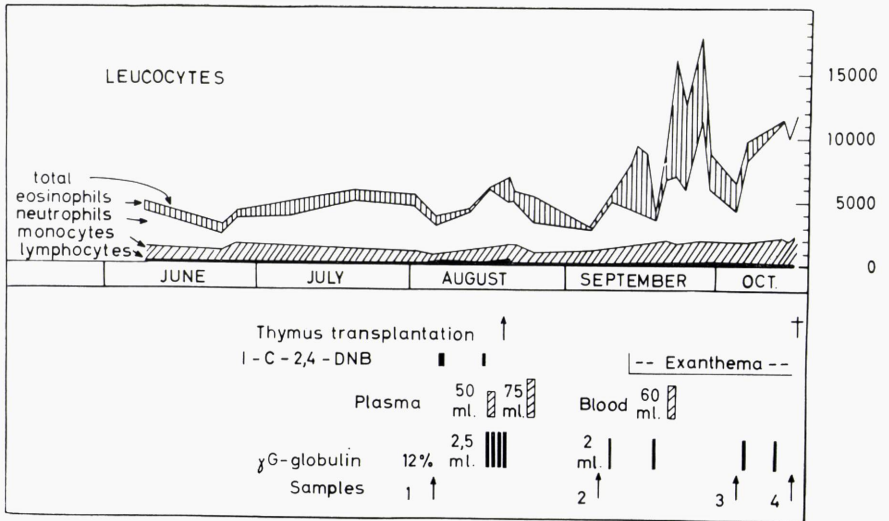


Figure 2. Survey of the clinical course.

On September 14 a general morbilliform rash appeared, probably unrelated to drugs. It gradually changed into a more reticular pattern and resulted in irregular pigmentation, both persisting until his death.

During most of the course he had a definite eosinophilia, which increased markedly when the rash developed, reaching a maximum level of 8,960 per μ l. The eosinophils responded normally to stress as the number decreased to 60 per μ l during a short period of dehydration; they also disappeared shortly before death (cf. Figure 2). The lymphocytopenia persisted; the highest value recorded was 440 per μ l. During the last few days of his life occasional plasma cells were seen in all blood smears (Figure 3). Monocytosis was present throughout the course, usually 1,500–2,000 cells per μ l. Occasionally, nucleated red cells were seen in the blood smear, but never more than four per 100 leucocytes.

The oral thrush was resistant to treatment with nystatin and pimarinic. The diarrhoea increased slowly and he terminally developed hypoproteinaemia, oedema and anaemia.

The pertussoid cough persisted, and the pulmonary infiltrations increased. He was initially treated with sulphonamides, later also with chloramphenicol and methicillin, with plasma and blood transfusions, and with injections of γ G-globulin. Throughout the infections the temperature remained normal until it rose during the last two days, and he died of pneumonia at seven months.

Autopsy. The body was markedly dystrophic, weighing 3,150 g and 56 cm long. There were pleural adhesions on the right side and marked bilateral bronchopneumonic changes. Microscopically, the normal lung structure was abolished by massive bronchopneumonia. In some areas infiltrations of neutrophilic granulocytes predominated; in other areas the infiltrations consisted chiefly of macrophages, numerous plasma cells, and some lymphocytes. Neither fungi nor *Pneumocystis carinii* were observed.

The *thymus gland* was situated normally and weighed 3 g; normal for this age 10–34 g (Roessle & Roulet 1932). The gland was lobulated; microscopically the structure was grossly abnormal (Figure 4a). There was no demarcation between cortex and medulla, and no Hassall's bodies were found. Extensive fibrosis was seen in some fields. Typical small lymphocytes were observed, but much fewer than normal. The gland was diffusely infiltrated by plasma cells. Some of these had a normal morphology; others

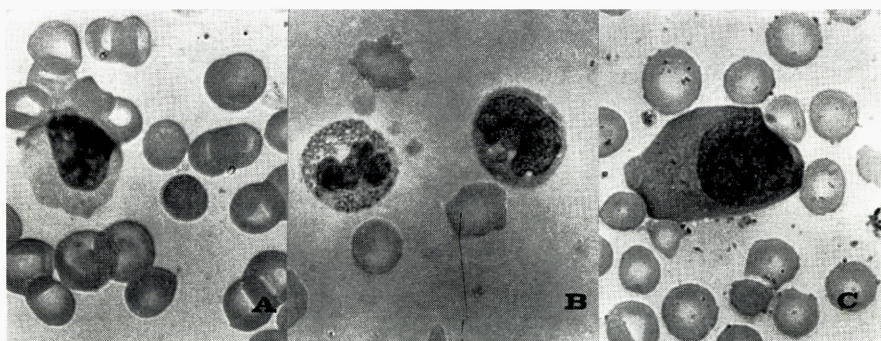


Figure 3. A, Peripheral blood smear showing a normally appearing lymphocyte.
 B, Buffy coat smear showing an eosinophilic granulocyte and a monocyte.
 C, Peripheral blood smear after the thymus transplantation showing a large plasma cell.

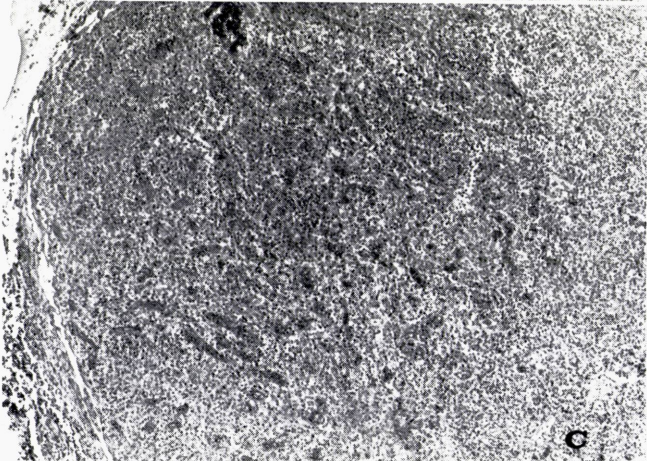
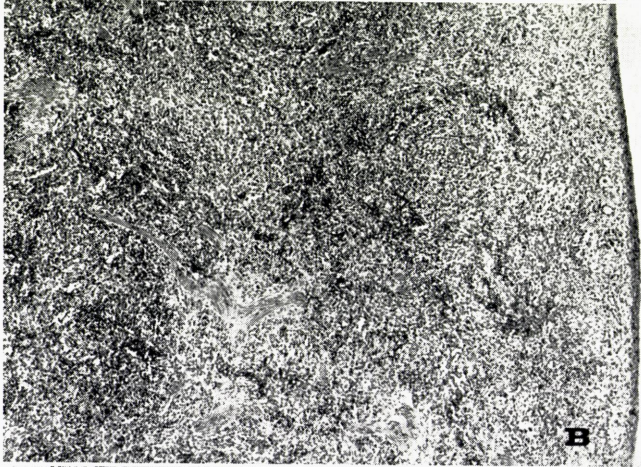
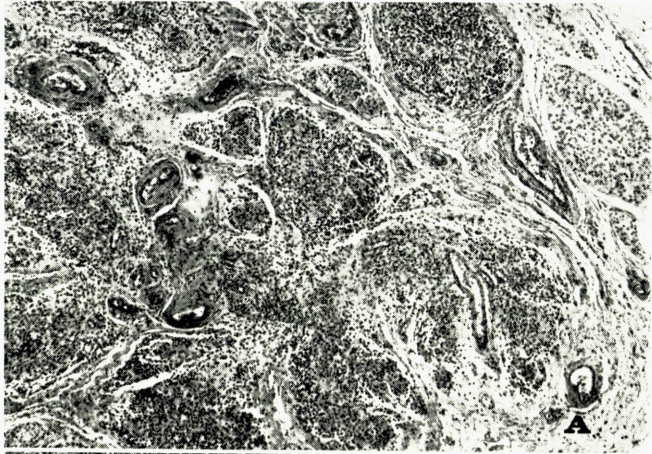


Figure 4. A, Thymus. B, Spleen. C, Lymph node.
Note hypoplasia and lack of follicle formation.

were elongated or irregularly shaped with varying nuclear chromatin pattern. Binuclear forms were also seen. By the methyl green-pyronin method, the cytoplasm stained more or less intensely red indicating a varying RNA content. The ratio of plasma cells to lymphocytes varied in different fields – plasma cells sometimes clearly predominating. The reticular cells had a normal morphology.

The *spleen* weighed 8 g; normal for this age 11–17 g (Roessle & Roulet 1932). The microscopic structure was abnormal (Figure 4b) with complete absence of ordinary lymphoid follicles. Around the central arteries many plasma cells and a few lymphocytes were accumulated, in some fields forming structures resembling rudimentary follicles. Large numbers of plasma cells and a few small lymphocytes were scattered throughout the tissue. The morphology of the plasma cells (Figure 10a) was as in the thymus.

Small *lymph nodes* were found in the mediastinum and in the mesentery. Microscopy revealed a few lymphocytes but no signs of follicle formation (Figure 4c). Plasma cells were abundant. Many lymph nodes contained necrotic areas with no surrounding cellular reaction.

Microscopy of the *gastrointestinal tract* revealed few cells and no Peyer's patches in the mucosa. The cells were mainly eosinophilic granulocytes, plasma cells and a few lymphocytes. Accumulations of plasma cells with typical Russell bodies could be seen.

The *thymus transplant* had preserved its normal lobulation. Epithelial-reticular cells predominated (Figure 5) and only few, scattered lymphocytes were present. Structures resembling Hassall's bodies were observed, but they could not be identified with certainty. There were no signs of graft rejection: no lymphocyte infiltration and no in-

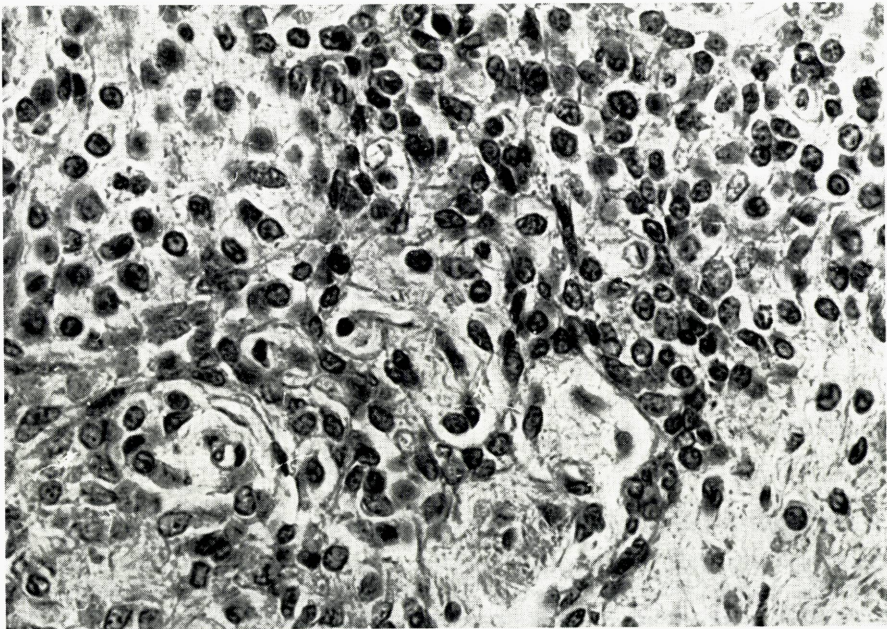


Figure 5. The thymus transplant. Note predominating epithelial-reticular cells and a few scattered lymphocytes.

flammatory changes in or around the graft. In the periphery there was a foreign-body reaction with giant cell formation. These cells contained a light refractive, filamentous substance, probably remnants of suture material.

IMMUNOLOGICAL STUDIES

Materials and methods for immunochemical studies

Immuno-electrophoresis and double diffusion tests in agar gel were performed as described elsewhere (Harboe *et al.* 1965). Density gradient ultracentrifugation was carried out according to Kunkel (1960).

Antisera for gel diffusion tests

Anti- γ G-globulin was prepared by immunization of rabbits with Cohn Fr. II γ G-globulin further purified by DEAE cellulose chromatography. Adsorption of this antiserum with pepsin-split γ G-globulin made it specific as judged by the following criteria. 1. In immuno-electrophoresis against human serum, it gave one precipitin line with the characteristic position and shape of γ G-globulin. 2. In double diffusion tests against highly purified γ G-, γ A-, and γ M-globulins, it precipitated only with γ G-globulin.

Anti- γ A-globulin was a commercial goat antiserum (Hyland Laboratories, Los Angeles, Cal.). *Anti- γ M-globulin* was obtained by immunizing rabbits with highly purified γ M-globulin followed by adsorption with γ G-globulin. These two antisera were specific for the respective proteins as judged by similar criteria.

Anti- κ chains and *anti- λ chains* were rabbit antisera obtained by immunization with purified Bence Jones proteins of the respective types adsorbed to acryl plast particles in complete Freund's adjuvant (Berglund 1965). They were specific in immuno-electrophoresis using myeloma sera previously typed by Mannik and Kunkel as a reference.

Concentrations of γ G- and γ M-globulin were determined by the technique of Fahey & McKelvey (1964). Reference solutions of γ G-globulin were prepared by dissolving weighed amounts of lyophilized, highly purified protein (donated by A. Björklund, AB Kabi, Stockholm, Sweden) in saline. These solutions were also used to construct a standard curve for determination of γ G-globulin concentrations by a modified Folin technique (Lowry *et al.* 1951). Reference solutions of γ M-globulin contained protein highly purified (Harboe & Deverill 1966) from sera of patients with Waldenström's macroglobulinaemia. The protein concentrations were determined by the Folin technique using the same standard curve as for γ G-globulin (Miller & Metzger 1965).

Tests for genetic factors of γ G-globulin were performed as previously described (Harboe 1959). The anti-Gm sera used gave test systems where the agglutination was inhibited by Gm(+) normal sera in dilutions up to at least 1/200 but not by Gm(-) sera even undiluted. The following reagents were used: For Gm(1), red cells coated with anti-D 2388 and the agglutinator Smejsa; for Gm(4) anti-D Ni./A.J.; for Gm(5) anti-D Bl./Smerud.

Materials and methods for immunohistochemical studies

Tissue specimens. Specimens were obtained 1-1½ hours post mortem from a supra-clavicular lymph node and from the site of the thymus transplant. At autopsy five hours after death, tissue was obtained from the recipient's thymus and spleen. The specimens were immediately placed in precooled 95 per cent ethanol, fixed and embedded (Sainte-Marie 1962). Sections were cut serially at six μ thickness.

Conjugated antisera. Rabbit anti-human γ G-globulin, globulin fraction conjugated with rhodamine B isothiocyanate (RBITC). The globulin fractions of the following antisera (Hyland Laboratories) were labelled with fluorescein isothiocyanate (FITC): goat anti-human γ A-globulin, goat anti-human γ M-globulin, rabbit anti-human albumin, and sheep anti-rabbit γ G-globulin. In diffusion in gel tests, the undiluted anti-human γ G- and γ A-globulin antisera showed a faint cross-reactivity. The other antisera appeared specific in these tests.

The antisera were sieved through Sephadex G 25 and adsorbed with acetone-dried mouse liver powder (Nairn 1964). The molecular ratio of fluorochrome to protein was within the range accepted for an optimal degree of conjugation (Fothergill 1964). The antisera were diluted to contain protein estimated (Wood *et al.* 1965, Cebra & Goldstein 1965) at 2.0 (anti- γ A) – 7.8 (anti- γ M) mg/ml.

Immunofluorescence techniques. Individual immunoglobulins were either disclosed by a direct technique (Nairn 1964), or simultaneously by double tracing in the following way: The tissue section was first exposed to RBITC-conjugated anti- γ G-globulin, rinsed for 15 minutes in three changes of isotonic phosphate buffered saline (pH 7.1), and exposed to FITC-conjugated anti- γ A- or anti- γ M-globulin. The incubation periods varied from 30 to 45 minutes at 22° C. In some experiments the sequence of application of antisera was reversed. After a final rinsing, the section was mounted in a semi-permanent mounting medium (Rodriguez & Deinhardt 1960). Kappa and λ chains were demonstrated by an indirect technique. The section was first incubated for 15 minutes with diluted (1:4) unlabelled rabbit anti- κ or anti- λ antiserum. It was subsequently rinsed for 15 minutes and then exposed to FITC-labelled anti-rabbit γ G-globulin for 45 minutes.

Controls. The anti- γ G-, anti- γ A-, and anti- γ M-globulin antisera employed did not produce fluorescence of mucosal tissue from patients with a- γ -globulinaemia, whereas specimens from normal subjects were stained by these antisera (Brandtzaeg *et al.* 1966). The sheep anti-rabbit γ G-globulin did not stain sections of human tissue.

Any staining reaction described below was shown to be immunologically specific. For example, when it is stated that plasma cells were stained by the anti- γ G-globulin, specificity was ascertained on adjoining sections by the following criteria:

1) Adsorption. Anti-human γ G-globulin produced fluorescence of sections from the spleen. After adsorption of the anti-serum with γ G-globulin in excess (1 mg γ G/ml anti-serum), no fluorescence (except autofluorescence) was seen; adsorption with γ A-globulin had no effect on the staining activity of the antiserum. Similar inhibition was achieved when the other antisera were adsorbed in excess with their corresponding antigens, but not when different antigens were used.

The following antigen preparations were used for adsorption: γ G-globulin was a Cohn Fr. II preparation (Nutritional Biochemicals Corp., Cleveland, Ohio) further purified by DEAE-cellulose chromatography. γ A-globulin was isolated from human parotid saliva by chromatography on DEAE-cellulose (Tomasi *et al.* 1965). The fraction eluted in the second step (pH 6.4 at 0.1 M) contained γ A-globulin and no other immunoglobulins. Cohn Fr. III (Hyland Laboratories) of human serum was used as a source rich in γ M-globulin. Dialysed urine from patients with multiple myeloma excreting only Bence Jones protein was used as sources of κ or λ chains.

2) Blocking. Complete blocking of the staining reactions was achieved for anti- γ G-, anti- γ A-, and anti- γ M-globulin in the following way: The tissue section was first incubated with one of the unlabelled anti- γ -globulin antisera for 60 minutes. The antiserum was used in a concentration 4–16 times higher than that of the corresponding labelled antiserum. The section was rinsed for 15 minutes and then fixed in 95 per cent

ethanol for 20 minutes at 4° C. After three short baths in buffered saline at pH 7.1 the section was exposed to a mixture of the unlabelled and the corresponding labelled antiserum for 25 to 45 minutes. No staining resulted. When normal goat serum was substituted for the unlabelled antiserum in the first and second steps of the blocking experiment, the staining was not inhibited.

Fluorescence microscopy and photomicrography

Fluorescence microscopy was carried out with a Leitz Ortholux Microscope, equipped with an Osram HBO 200 light source, UG 1 and BG 38 primary filters and a K 430 secondary filter. Photographs of the immunofluorescence preparations were taken with 35 mm colour-reversal film for daylight (High Speed Ektachrome, 23 DIN) at exposure times from 90 to 300 seconds.

Methyl green-pyronin staining. For evaluation of the plasma cell population, sections adjoining the immunofluorescence preparation were stained by Kurnick's method (1960) with slight modifications.

RESULTS

Studies of plasma proteins

The proteins of four serum samples were compared by immunoelectrophoresis. Sample 1 was obtained two weeks before the thymus transplantation, sample 2 nineteen days after the transplantation, and samples 3 and 4 about seven and eight weeks after the transplantation (cf. Figure 2). In each plate serum from a normal adult was included to illustrate the activity of the antisera.

In immunoelectrophoresis the anti- γ M-globulin produced no precipitin line with serum samples 1 and 2, whereas marked γ M-globulin lines occurred with samples 3 and 4 (Figure 6). The concentration of γ M-globulin increased considerably during the observation period (Table II).

Density gradient ultracentrifugation showed that the protein reacting with the anti- γ M-globulin antiserum sedimented as a typical γ M-globulin (Figure 7). It differed, however, from normal γ M-globulin by being electrophoretically homogeneous and by containing only λ chains. These properties are typical of monoclonal γ M-globulins (Mannik & Kunkel 1962, Fahey 1962, Fahey & Solomon 1963).

TABLE II
Concentration of γ -globulins in patient's serum

Date	γ G-globulin (mg/ml)	γ M-globulin (mg/ml)
August 5	0.7	not detectable*
September 7	4.7	0.08
October 6	4.5	0.5
October 15	9.7	0.5

* Less than 0.02 mg/ml

Immuno-electrophoresis with anti- γ G-globulin (Figure 8) showed that the concentration of γ G-globulin was low in sample 1. With sample 4, a localized deviation of the precipitin line towards the antibody reservoir occurred. This is typical of an electrophoretically homogeneous, monoclonal γ G-globulin of high concentration. This protein contained only λ chains. Paper electrophoresis (Figure 9) clearly demonstrated a decreased concentration of γ -globulin in sample 1 and a sharp γ -globulin band in sample 4.

The homogeneous γ G-globulin sedimented on density gradient ultracentrifugation like normal γ G-globulin and slower than the monoclonal γ M-globulin described above (Figure 7). Thus, there were two distinct monoclonal λ -type γ -globulins in the serum, and not a highly abnormal 'hybrid' molecule containing both γ - and μ -chains. The two monoclonal proteins had

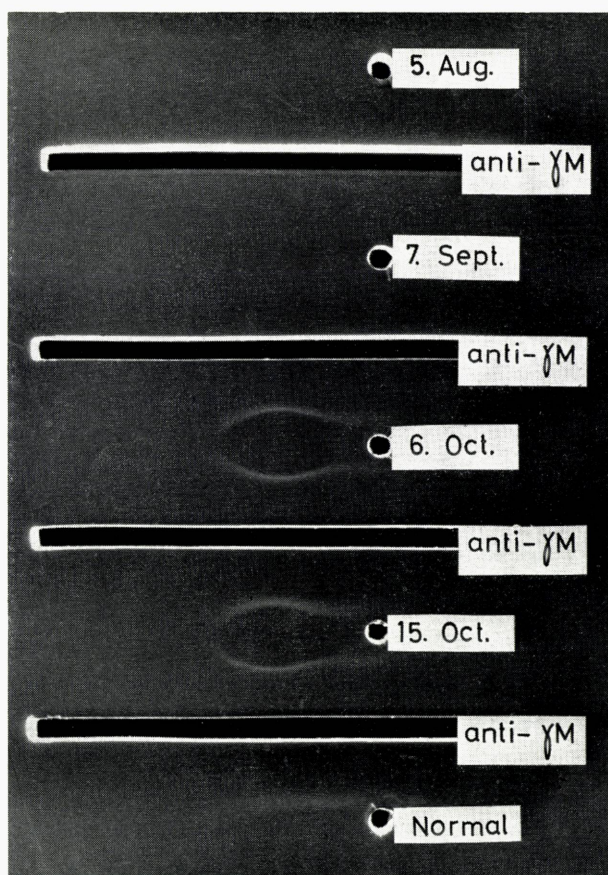


Figure 6. Immunoelectrophoresis with specific anti- γ M-globulin antiserum.

Figure 7. Density gradient ultracentrifugation of serum sample 4. The solid line shows the protein concentration. The short curved lines indicate the presence and relative amount of γ G- and γ M-globulin as found by diffusion in gel analyses.

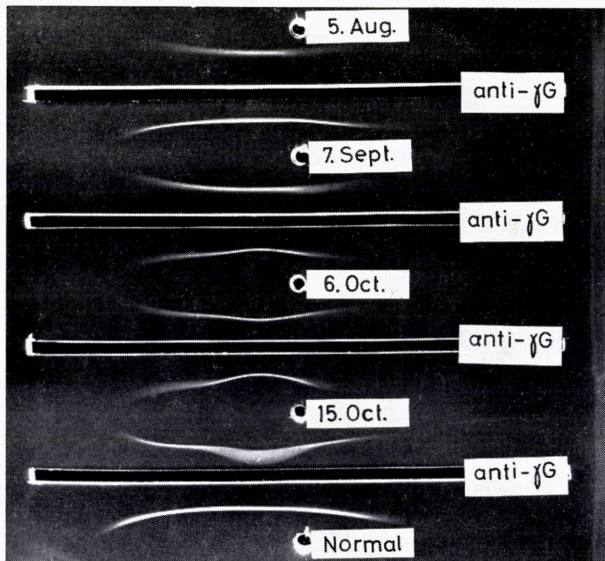
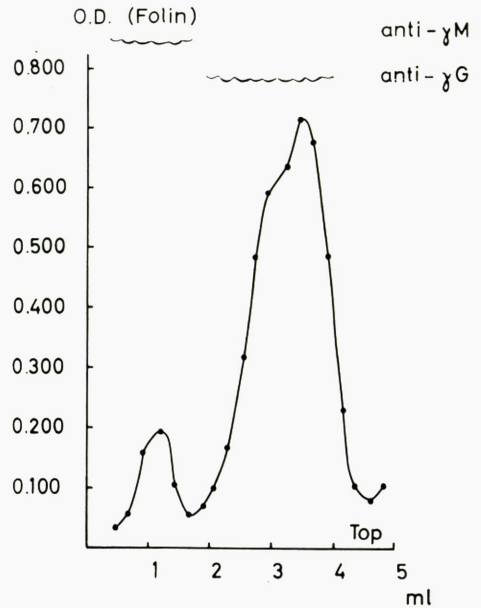


Figure 8. Immunoelectrophoresis with specific anti- γ G-globulin antiserum.

similar electrophoretic mobility in routine immunoelectrophoresis, but could be separated by doubling the electrophoresis time.

In immunoelectrophoresis and gel-diffusion tests with potent specific anti-

serum, γ A-globulin could not be detected in sample 1, but appeared in the three other samples. The low concentration did not permit further characterization of this protein.

The two monoclonal proteins could occur in the patient's serum after the thymus transplantation because of: 1. Infusion of plasma. Sera from the three plasma donors were examined, but all contained normal γ -globulins. 2. Therapeutic administration of γ G-globulin. The different batches of γ -globulin (AB Kabi, Stockholm, Sweden) given were tested, but did not contain proteins corresponding to the two monoclonal γ -globulins. 3. Production by the patient. Evidence for this was sought by immunohistochemical studies, since the first two possibilities could be excluded.

Immunohistochemical studies

The *spleen* contained more plasma cells than does normal splenic tissue. Experiments with conjugated anti- γ G-globulin antiserum, with controls for specificity as outlined above, demonstrated that the cytoplasm of the majority of the plasma cells contained γ G-globulin. Specific fluorescence was seen in both typical and atypical plasma cells. The intensity of the fluorescence varied considerably, probably signifying varying contents of γ G-globulin. Many cells with scanty cytoplasm resembling lymphocytes contained γ G-globulin as indicated by a thin fluorescent rim around the nucleus. Staining for κ chains showed very few (3–15) brightly fluorescing cells in each section, – less than one per cent of the total number of γ G-containing cells (Figure 10e). Sections stained for λ chains contained numerous cells fluorescing with varying degrees of intensity (Figure 10f). Their number, distribution, and morphology corresponded to the γ G-globulin containing cells.

Staining for γ A-globulin showed 8–16 fluorescing cells in each section: less than one per cent of the number of cells containing γ G-globulin. A similar small number contained γ M-globulin as evidenced by their reaction

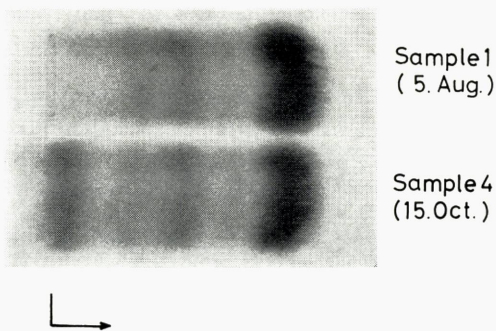


Figure 9. Paper electrophoresis of serum samples 1 and 4.

with labelled anti- γ M-globulin. The connective tissue septa in some areas exhibited a faint fluorescence, mainly for γ G-globulin. A similar background fluorescence was observed in all of the specimens and occurred also after exposure to conjugated anti-albumin, but this antiserum did not produce specific staining of plasma cells.

The *lymph node* specimen was crowded by round cells; many were pyronophilic and stained specifically for γ G-globulin. Some of them exhibited the characteristic plasma cell morphology; other cells were poorly defined probably because of disintegration *in vivo*. Only a couple of γ A- and no γ M-globulin containing cells were detected.

The patient's own *thymic tissue* was diffusely and heavily infiltrated by plasma cells. The majority of these cells as well as many blast cells and lymphocytes were specifically stained for γ G-globulin (Figure 10b-d). Sections examined for κ chains showed about 30 fluorescing cells: less than ten per cent of the total number of γ G-globulin containing cells. Staining for λ chains revealed numerous specifically fluorescing cells. Their number and distribution corresponded to that observed for γ G-globulin containing cells. From 30 to 50 cells in each section were stained with anti- γ A-globulin. Some of these were typical plasma cells (Figure 10c); others had the size of lymphocytes with a narrow rim of fluorescent material. About 50 cells in each section fluoresced specifically for γ M-globulin (Figure 10d). Many of these cells looked like lymphocytes; some were elongated variants of plasma cells.

LEGEND FOR FIGURE 10

- A Section of spleen stained with methyl green-pyronin. Note dense infiltration of pyronophilic plasma cells. Original magnification x 400.
- B Section of thymus exposed to FITC-conjugated anti- γ A-globulin antiserum adsorbed with γ G-globulin, followed by RBITC-conjugated anti- γ G-globulin antiserum adsorbed with γ A-globulin. Note numerous γ G-globulin containing cells; a few cells in the upper part stained for γ A-globulin. Original magnification x 60.
- C Same immunofluorescence preparation as in Figure 10B. Numerous plasma cells and lymphocytes contain γ G-globulin; a single plasma cell contains γ A-globulin. Original magnification x 300.
- D Section of thymus exposed to FITC-conjugated anti- γ M-globulin antiserum adsorbed with γ G-globulin, followed by RBITC-conjugated anti- γ G-globulin antiserum adsorbed with γ A-globulin. Several plasma cells and lymphocytes contain γ G-globulin; a single plasma cell contain γ M-globulin. Original magnification x 300.
- E Section of spleen exposed to rabbit anti- κ chains, followed by FITC-conjugated anti-rabbit γ G-globulin antiserum. A single cell contains κ polypeptide chains. Original magnification x 160.
- F Section of spleen exposed to rabbit anti- λ chains adsorbed with Bence Jones protein Type K, followed by FITC-conjugated anti-rabbit γ G-globulin antiserum. Numerous cells contain λ polypeptide chains. Original magnification x 160.

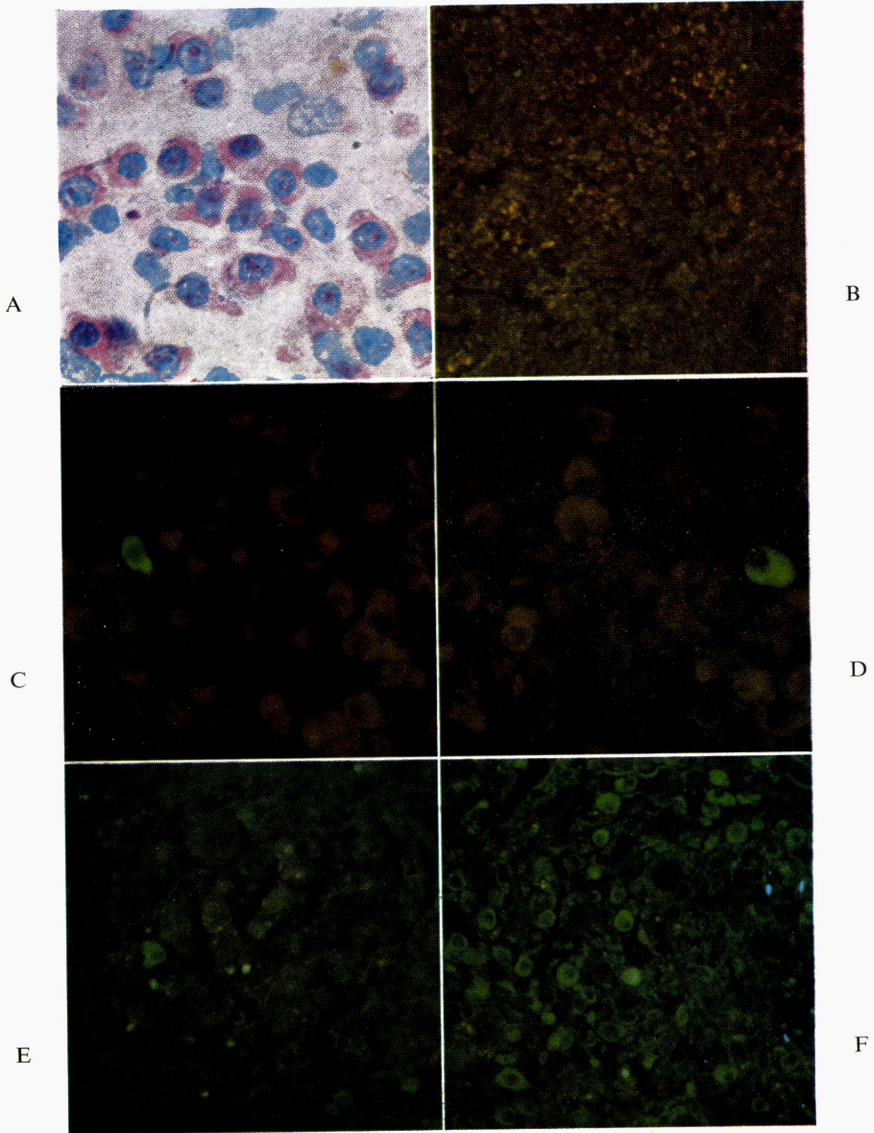


Figure 10

TABLE III
Genetic factors in γ G-globulin

	Phenotype	Probable genotype
Patient's mother	Gm(-1,4,5)	$Gm^{4,5}/Gm^{4,5}$
Patient's father	Gm(-1,4,5)	$Gm^{4,5}/Gm^{4,5}$
Patient's serum Aug. 5 at 4½ months of age, prior to administration of γ -globulin	Gm(-1,4,5)	$Gm^{4,5}/Gm^{4,5}$
The monoclonal γ G-globulin	Gm(1,-4,-5)	
Thymus donor's mother	Gm(-1,4,5)	$Gm^{4,5}/Gm^{4,5}$
Thymus donor's father	Gm(1,4,5)	$Gm^1/Gm^{4,5}$
Thymus donor	not testable	$Gm^1/Gm^{4,5}$ or $Gm^{4,5}/Gm^{4,5}$

Tissue from the *site of thymus implantation* consisted of muscle fibres, connective tissue, and thymic tissue with predominating epithelial-reticular elements. Only about 20 pyroninophilic cells were detected in each section. Some of these were blast cells or immature plasma cells. By the immunofluorescence technique, the connective tissue ground substance appeared to contain low concentrations of albumin and immunoglobulins, mainly γ G-globulin. Only a few, scattered immunoglobulin-containing cells were present in the sections.

Studies of genetic factors

Human γ G-globulin contains a variety of genetic factors (Grubb 1956). Some of these were used as markers in an attempt to trace the origin of the cells producing the monoclonal γ G-globulin.

The patient's parents were both Gm(-1,4,5) and thus homozygous for the genes Gm^4 and Gm^5 . The patient's genetic type should therefore be identical with that of his parents. The sample obtained on August 5 (sample 1) was tested for genetic factors. At that time, the patient had not received transfusions or γ G-globulin parenterally. The type was Gm(-1,4,5) as expected (Table III).

The results of tests for genetic factors in samples 1 and 4 are summarized in Table IV. The ability of the γ G-globulin to inhibit the various specific test systems was compared with pooled normal γ G-globulin in identical concentrations.

Typing of sample 1 showed that the Gm(4) and Gm(5) factors were characteristic of the patient himself. Later, Gm(4) and Gm(5) γ G-globulin was given to the patient therapeutically. When the samples were compared with regard to inhibiting capacity per mg γ G-globulin, however, it appeared that the activity in both test systems decreased from August 5 to October 15. Thus, the

TABLE IV

Tests for genetic factors in γ G-globulin of serum samples obtained before and after thymus transplantation compared with pooled normal γ G-globulin

Test	Material	Concentration of γ G-globulin (mg/ml)									
		1.4	0.7	0.35	0.18	0.09	etc.				
Gm(1)	pooled γ G	0	0	0	0	0	1	2	3	3	3
	P.E. Aug. 5	nt	3	3	3	3	3	3	3	3	3
	P.E. Oct. 15	0	0	0	0	0	0	0	2	3	3
Gm(4)	pooled γ G	0	0	0	0	0	1	3	3	3	3
	P.E. Aug. 5	nt	0	0	0	0	1	3	3	3	3
	P.E. Oct. 15	0	0	1	3	3	3	3	3	3	3
Gm(5)	pooled γ G	0	0	0	1	3	3	3	3	3	3
	P.E. Aug. 5	nt	0	0	1	3	3	3	3	3	3
	P.E. Oct. 15	0	2	3	3	3	3	3	3	3	3

Controls: Sensitized cells and saline: 0

Test materials and sensitized cells: 0

1, 2, 3 denote strength of agglutination - 0, no agglutination - nt, not tested

proportion of γ G-globulin molecules lacking Gm(4) and Gm(5) increased considerably during this period.

Sample 1 did not inhibit the Gm(1) test system at the highest concentration tested (0.7 mg/ml), whereas sample 4 had a marked inhibiting capacity. Thus, Gm(1) γ G-globulin had appeared in the child's circulation. The inhibiting activity of sample 4 in the Gm(1) test system was even significantly greater than that of pooled normal γ G-globulin. This indicates that sample 4 contained a larger proportion of Gm(1) γ G-globulin molecules than pooled normal γ G-globulin even though the child was Gm(-1) as proved by typing of sample 1 and his parents. We concluded from these findings that the monoclonal γ G-globulin in the patient's serum was Gm(1,-4,-5).

Since the monoclonal γ G-globulin contained a genetic factor lacking in sample 1 and the patient's parents, it appeared that this genetic factor might be characteristic of the thymus donor. Its father was Gm(1,4,5) and the mother Gm(-1,4,5); half the offspring of this mating is of genotype $Gm^1/Gm^{4,5}$ and half $Gm^{4,5}/Gm^{4,5}$ (Table III).

DISCUSSION

Hypo- γ -globulinaemia, severe lymphocytopenia, pulmonary infections, persistent diarrhoea, and severe dystrophy established the diagnosis of 'Swiss type of hypo- γ -globulinaemia'. The findings at autopsy were also typical with hypoplasia of the lymphoid system including the thymus. Plasma cells are usually lacking in this disease (Barandun *et al.* 1958, Peterson *et al.* 1965), and prior to the thymus transplantation not a single plasma cell was found

in three smears of bone marrow containing several thousand nucleated cells, or in the peripheral blood. After thymus transplantation, small numbers of plasma cells (1–2 per cent of the white cells) were regularly observed in smears of peripheral blood (cf. Figure 3c). The serum protein changes and the immunohistochemical observations indicated that the thymus transplantation had induced the pronounced plasma cell infiltrations revealed in lymphoid tissues at autopsy.

Several observations provided evidence for immunological deficiency: The low serum concentration of γ G- and lack of γ A- and γ M-globulin 138 days after birth indicated a marked deficiency in the production of circulating antibodies. In addition, isohaemagglutinins could not be demonstrated on repeated examinations. Antibody production after antigenic stimulation was not investigated since bilateral renal cortical necrosis has been observed after such stimulation in this disease (Hitzig *et al.* 1958). Skin tests with 1-chloro-2,4-dinitro-benzene were negative. Thus the patient did not exhibit delayed type hypersensitivity reactions, and, moreover, did not reject the thymus transplant.

Marked eosinophilia was observed throughout the course of the disease – an unusual finding in the Swiss type of hypo- γ -globulinaemia (Hitzig 1963). The functions of the eosinophilic granulocytes are only partially established. The cells accumulate locally at the site of immune reactions, particularly in the immediate type I (anaphylactic) reactions (Coombs & Gell 1963), and are capable of engulfing antigen-antibody complexes (Sabesin 1963). Marked eosinophilia was observed in a child with the congenital sex linked form of hypo- γ -globulinaemia during massive *Ascaris* infection (Huntley & Costas 1965); the eosinophilia was considered to be unrelated to antigen-antibody reactions. The ability to exhibit delayed hypersensitivity reactions is, at least partly, intact in this disease. In our patient who had severe defects both in production of circulating antibodies and in delayed hypersensitivity, the marked eosinophilia is even more striking and indicates that eosinophilia is not necessarily a reflection of immune reactions.

The cellular origin of haematogenous tissues is unknown; they may arise from a single pluripotential stem cell, or each cell line may have a distinct stem cell. Experiments where mouse embryo liver cells, distinguishable by the T6 marker chromosome, were injected into lethally irradiated recipients (Taylor 1965) indicated that both haematopoietic and lymphopoietic capacities resided in the same cell, and that this cell was a precursor of the thymus lymphocytes both in adult and embryonic life. It appears significant in this context that the Swiss type of hypo- γ -globulinaemia which is characterized by extreme hypoplasia of lymphoid tissues including the thymus, is associated with normal production of myeloid cells, thrombocytes and erythrocytes.

Following the thymus transplantation, a monoclonal γ G- and a monoclonal γ M-globulin appeared in the patient's serum. The experiments showed that these proteins did not originate from transfusions or parenteral administration of γ -globulin, and we concluded that they were synthesized in the patient.

The immunohistochemical investigations provided the morphological correlate to the findings in serum by demonstrating numerous plasma cells containing – and presumably synthesizing – γ G-globulin with λ chains (Figure 10b–c). Cells containing γ M-globulin were also found (Figure 10d), but their number was too low to explain the relatively high concentration of monoclonal γ M-globulin in serum samples 3 and 4. The main synthesis of γ M-globulin probably occurred in tissues other than those examined immunohistochemically, e.g. in the intestinal mucosa where γ M-globulin is produced normally (Crabbe *et al.* 1965), and where accumulations of plasma cells were observed by conventional histological techniques.

γ A-globulin was not detected in serum sample 1, but was present in low concentration in the later samples. The immunohistochemical studies indicated that γ A-globulin was synthesized in the patient at the time of death (Figure 10b–c). The lack of γ A-globulin in sample 1 suggested, but did not prove, that this synthesis was also induced by the thymus transplant.

Double-tracing studies on human lymphoid tissues have indicated that individual plasma cells usually synthesize only one type of γ -globulin at a given time (Chiappino & Pernis 1964, Bernier & Cebra 1965). When γ G-globulin was traced simultaneously with γ A- or γ M-globulin, single cells appeared to contain only one of these proteins (Figure 10c–d).

Tests for genetic factors elucidated the origin of the cells producing the monoclonal γ G-globulin. The patient and his parents were Gm(–1), whereas the monoclonal γ G-globulin contained the Gm(1) factor. Typing of the thymus donor's parents showed that its father was Gm(1). Evidently, then, the monoclonal γ G-globulin was synthesized by donor type cells originating from the thymus graft. The monoclonal γ M-globulin was probably also produced by cells originating from the thymus graft, but this could not be proved since genetic factors specific for γ M-globulin have not yet been delineated in man.

Neonatally thymectomized mice are immunologically deficient, but may recover immunological capacity by early thymus grafting (Miller 1961) or by intraperitoneal infusion of large numbers of thymic cells (Yunis *et al.* 1964). Simonsen's discriminating spleen assay indicates that the recovery is largely due to cells of host origin, but under some circumstances the recovery is clearly of donor type (Dalmaso *et al.* 1963, Yunis *et al.* 1964).

Information on the mechanisms of immunological recovery has emerged from experiments with cytologically marked thymus grafts. Donor type cells migrate from these grafts and populate peripheral lymphoid tissues, but the

number of mitoses of donor type in peripheral lymphoid tissues is usually rather low (Miller 1962a, Harris & Ford 1964). This number increases considerably after antigenic stimulation (Leuchars *et al.* 1964, Davies *et al.* 1966), but it is not known to what extent the dividing cells are responsible for the production of specific antibodies. These observations are paralleled and extended by our findings: cells of donor type left the thymus graft, proliferated in peripheral lymphoid tissues, and produced discrete γ -globulins.

The monoclonal nature of these proteins facilitated their identification and made it feasible to show that the γ G-globulin was synthesized by cells of donor origin. The immunohistochemical observations also indicated that most, if not all, of the γ G-globulin production induced by the thymus transplant was concerned with the monoclonal Gm(1) γ G-globulin. The vast majority of the γ G-globulin containing cells contained λ chains (Figure 10e-f). If significant amounts of heterogeneous γ G-globulins were synthesized in addition, one would expect that more plasma cells contained κ chains.

The concentration of γ A-globulin in serum was too low to establish its mono- or polyclonal nature. With this reservation, it appeared that only few clones of cells synthesized γ -globulins after the thymus transplantation. This observation indicates that the cells originating from the graft had a limited functional capacity, and that production of a heterogeneous population of specific antibodies may be difficult to induce by transplantation of foetal thymus in immunological deficiency diseases in man.

Epithelial-reticular cells predominated in the thymus transplant and only few lymphoid elements were seen. This histological picture is similar to that of embryonic thymus transplants placed intraperitoneally in Millipore chambers in neonatally thymectomized mice (Osoba & Miller 1964). The epithelial-reticular cells remain intact in these chambers, whereas the lymphoid cells disappear; cell migration into the graft is prevented by the Millipore membrane. Conventional thymus grafts in neonatally thymectomized mice are, however, entirely populated by lymphoid cells of host origin (Dukor *et al.* 1965) after the disappearance of the donor type lymphocytes. Thus, in spite of the immunological deficiency of these mice, lymphoid cells are available for repopulation of the graft which then retains its normal structure (Dukor *et al.* 1965). In our patient with an abnormal and extremely deficient lymphoid tissue, it appeared that cell migration into the graft was negligible.

Reconstitution of immunological competence after neonatal thymectomy has been intensively investigated in mice. These experiments provide an important laboratory model for immunological deficiency disease in man, especially for the Swiss form of hypo- γ -globulinaemia. Early thymus grafting (Miller 1961) or large numbers of thymus cells (Yunis *et al.* 1964) will reconstitute the majority of the mice completely. When wasting disease has

developed, immunological recovery is considerably more difficult to achieve. Thymus grafting alone does not suffice, but injection of syngeneic adult spleen or thymus cells may completely reverse the wasting (Yunis *et al.* 1965). It may also be reversed by injection of hemiallogeneic or allogeneic spleen cells in certain strain combinations. With more marked tissue incompatibility, such injection leads to a malignant form of graft-versus-host reaction with accelerated wasting and death (Miller 1962b, Good *et al.* 1962, Yunis *et al.* 1965).

In our case, the thymus graft was functioning, and increasing concentrations of donor type γ G-globulin occurred in the recipient's circulation. The clinical course and the wasting disease, however, were unaffected. Increased numbers of lymphocytes in the peripheral blood have previously been observed after thymus transplantation (Hitzig *et al.* 1965), but the disease progressed to death. Since wasting disease can be completely reversed in neonatally thymectomized mice by giving immunologically component cells – provided these cells have a sufficient degree of tissue compatibility – it appears that successful restoration of immunological capacity and reversion of wasting disease may be possible in the Swiss form of hypo- γ -globulinaemia. The requirement for successful therapy appears to be proper selection of the lymphoid tissue donor, based on better knowledge of histocompatibility antigens in man.

ACKNOWLEDGEMENTS

We wish to thank Dr. T. Dahle, who provided serum samples from the parents of the thymus donor, and Mrs. Johanna Deverill, Miss Wencke Hansen and Mr. Michael Jeremic for skilled technical assistance. Dr. O. P. Foss kindly performed the paper electrophoresis shown in Figure 9.

We are most grateful to A/S Kabi, Norway, for their generosity in defraying the cost of the colour plate.

REFERENCES

- Barandun, S., Cottier, H. & Hässig, A. (1959) 'New aspects of agammaglobulinemia and antibody deficiency syndrome.' 1st Int. Symposium on Immunopathology, Basel/Seelisberg. Benno Schwabe, Basel/Stuttgart, pp. 60–67.
- Berglund, G. (1965) 'Preparation of antiserum to an antigen of low molecular weight.' *Nature* (Lond.) **206**, 523–24.
- Bernier, G. M. & Cebra, J. J. (1965) 'Frequency distribution of α , γ , κ and λ polypeptide chains in human lymphoid tissues.' *J. Immunol.* **95**, 246–53.
- Brandtzaeg, P., Gjeruldsen, S. T., Fjellanger, I. & Berdal, P. 'Immunoglobulins in mucous membranes.' In preparation.
- Cebra, J. J. & Goldstein, G. (1965) 'Chromatographic purification of tetramethyl-rhodamine-immune globulin conjugates and their use in the cellular localization of rabbit γ -globulin polypeptide chains.' *J. Immunol.* **95**, 230–45.

- Chiappino, G. & Pernis, B. (1964) 'Demonstration with immunofluorescence of 19S macroglobulins and 7S gamma globulins in different cells of the human spleen.' *Path. et Microbiol.* (Basel) **27**, 8-15.
- Coombs, R. R. A. & Gell, P. G. H. (1963) 'The classification of allergic reactions underlying disease.' In *Clinical Aspects of Immunology*. Gell, P. G. H. & Coombs, R. R. A. (eds.) Blackwell, Oxford, pp. 317-37.
- Crabbe, P. A., Carbonara, A. O. & Heremans, J. F. (1965) 'The normal human intestinal mucosa as a major source of plasma cells containing γ A-immunoglobulin.' *Lab. Invest.* **14**, 235-48.
- Dalmaso, A. P., Martinez, C., Sjodin, K. & Good, R. A. (1963) 'Studies on the role of the thymus in immunobiology.' *J. exp. Med.* **118**, 1089-1109.
- Davies, A., Leuchars, E., Wallis, V. & Koller, P. (1966) 'The mitotic response of thymus-derived cells to antigenic stimulus.' *Transplantation* (in press).
- Dukor, P., Miller, J. F. A. P., House, W. & Allman, V. (1965) 'Regeneration of thymus grafts. I. Histological and cytological aspects.' *Transplantation* **3**, 639-68.
- Fahey, J. L. (1962) 'Heterogeneity of γ -globulins.' *Advanc. Immunol.* **2**, 41-109.
- Fahey, J. L. & Solomon, A. (1963) 'Two types of γ -myeloma proteins, β_{2A} -myeloma proteins, γ -macroglobulins, and Bence Jones proteins identified by two groups of common antigenic determinants.' *J. clin. Invest.* **42**, 811-22.
- Fahey, J. L. & McKelvey, E. M. (1964) 'Quantitative determination of serum immunoglobulins in antibody-agar plates.' *J. Immunol.* **94**, 84-90.
- Fothergill, J. E. (1964) 'Properties of conjugated serum proteins.' In *Fluorescent Protein Tracing*. Nairn, R. C. (ed.) Livingstone, London, pp. 34-59.
- Glanzmann, E. & Riniker, P. (1950) 'Essentielle Lymphocytophthise - Ein neues Krankheitsbild aus der Säuglingspathologie.' *Ann. paediat.* (Basel) **175**, 1-32.
- Glaser, K., Limarzi, L. R. & Poncher, H. G. (1950) 'Cellular composition of the bone marrow in normal infants and children.' *Pediatrics* **6**, 789-824.
- Good, R. A., Dalmaso, A. P., Martinez, C., Archer, O. K., Pierce, J. C. & Papermaster, B. W. (1962) 'The role of the thymus in development of immunologic capacity in rabbits and mice.' *J. exp. Med.* **116**, 773-96.
- Good, R. A., Martinez, C., Dalmaso, A. & Papermaster, B. W. (1963) 'Studies on the role of thymus in developmental biology - with a consideration of the association of thymus abnormalities to clinical disease.' 3rd Int. Symposium on Immunopathology, La Jolla, Cal. Benno Schwabe, Basel/Stuttgart, pp. 177-200.
- Grubb, R. (1956) 'Agglutination of erythrocytes coated with 'incomplete' anti-Rh by certain rheumatoid arthritic sera and some other sera. The existence of human serum groups.' *Acta path. microbiol. scand.* **39**, 195-97.
- Harboe, M. (1959) 'Quantitative studies on the haemagglutination inhibition reaction for determination of the Gm types.' *Acta path. microbiol. scand.* **47**, 199-208.
- Harboe, M., Deverill, J. & Godal, H. C. (1965) 'Antigenic heterogeneity of Waldenström type γ M-globulins.' *Scand. J. Haemat.* **2**, 137-47.
- Harboe, M. & Deverill, J. (1966) 'Structural relationship between γ G- and γ M-globulin in man.' *Acta med. scand.* **179**, suppl. 445, 74-79.
- Harris, J. E. & Ford, C. E. (1964) 'Cellular traffic of the thymus: Experiments with chromosome markers. Evidence that the thymus plays an instructional part.' *Nature* (Lond.) **201**, 884-85.
- Hitzig, W. H. (1963) 'Immunobiologische Reaktionen des cellularen und des humoralen Systems.' *Schweiz. med. Wschr.* **93**, 1433-44.
- Hitzig, W. H., Biró, Z., Bosch, H. & Huser, H. J. (1958) 'Agammaglobulinämie und

- Alymphocytose mit Schwund des lymphatischen Gewebes.' *Helv. paediat. Acta* **13**, 551-85.
- Hitzig, W. H., Kay, H. E. M. & Cottier, H. (1965) 'Familial lymphopenia with agammaglobulinaemia ("Swiss type of agammaglobulinaemia"): attempt of treatment by implantation of foetal thymus.' *Lancet* **II**, 151-54.
- Huntley, C. C. & Costas, M. C. (1965) 'Eosinophilia and agammaglobulinemia.' *Pediatrics* **36**, 425-28.
- Kunkel, H. G. (1960) 'Macroglobulins and high molecular weight antibodies.' In *The Plasma Proteins*. Putnam, F. W. (ed.) Academic Press, New York/London, pp. 279-307.
- Leuchars, E., Cross, A. M., Davies, A. J. S. & Wallis, V. J. (1964) 'A cellular component of thymic function.' *Nature* (Lond.) **203**, 1189.
- Lowry, O. H., Rosebrough, N. J., Farr, A. L. & Randall, R. J. (1951) 'Protein measurement with the Folin phenol reagent.' *J. biol. Chem.* **193**, 265-75.
- Mannik, M. & Kunkel, H. G. (1962) 'Classification of myeloma proteins, Bence Jones proteins, and macroglobulins into two groups on the basis of common antigenic characters.' *J. exp. Med.* **116**, 859-77.
- Miller, J. F. A. P. (1961) 'Immunological function of the thymus.' *Lancet* **II**, 748-49.
- Miller, J. F. A. P. (1962) 'Role of the thymus in transplantation immunity.' *Ann. N. Y. Acad. Sci.* **99**, 340-54.
- Miller, J. F. A. P. (1962) 'Effect of neonatal thymectomy on the immunological responsiveness of the mouse.' *Proc. roy. Soc.* **B 156**, 415-28.
- Miller, F. & Metzger, H. (1965) 'Characterization of a human macroglobulin.' *J. biol. Chem.* **240**, 3325-33.
- Nairn, R. C. (1964) 'Immunological tracing: general considerations.' In *Fluorescent Protein Tracing*. Nairn, R. C. (ed.) Livingstone, London, pp. 103-37.
- Osoba, D. & Miller, J. F. A. P. (1964) 'The lymphoid tissues and immune responses of neonatally thymectomized mice bearing thymus tissue in millipore diffusion chambers.' *J. exp. Med.* **119**, 177-94.
- Pears, A. G. E. (1960) *Histochemistry - Theoretical and Applied*. Churchill, London, 998 pp.
- Peterson, R. D. A., Cooper, M. D. & Good, R. A. (1965) 'The pathogenesis of immunologic deficiency diseases.' *Amer. J. Med.* **38**, 579-604.
- Rodriguez, J. & Deinhardt, F. (1960) 'Preparation of a semipermanent mounting medium for fluorescent antibody studies.' *Virology* **12**, 316-17.
- Rosen, F. S., Gitlin, D. & Janeway, C. A. (1962) 'Allymphocytosis, agammaglobulinaemia, homografts, and delayed hypersensitivity: study of a case.' *Lancet* **II**, 380-81.
- Roessle, R. & Roulet, F. (1932) *Mass und Zahl in der Pathologie*. Springer Verlag, Berlin, 144 pp.
- Sabesin, S. M. (1963) 'A function of the eosinophil: Phagocytosis of antigen-antibody complexes.' *Proc. Soc. exp. Biol.* (N.Y.) **112**, 667-70.
- Sainte-Marie, G. (1962) 'A paraffin embedding technique for studies employing immunofluorescence.' *J. Histochem. Cytochem.* **10**, 250-56.
- Sommerfelt, S. C. (1953) 'Paper electrophoresis of isolated plasma protein fractions.' *Scand. J. clin. Lab. Invest.* **5**, 299-307.
- Taylor, R. B. (1965) 'Pluripotential stem cells in mouse embryo liver.' *Brit. J. exp. Path.* **46**, 376-83.
- Tobler, R. & Cottier, H. (1958) 'Familiäre Lymphopenie mit Agammaglobulinämie und schwerer Moniliiasis.' *Helv. paediat. Acta* **13**, 313-38.

- Tomasi, T. B., Tan, E. M., Solomon, A. & Prendergast, R. A. (1965) 'Characteristics of an immune system common to certain external secretions.' *J. exp. Med.* **121**, 101-24.
- Wood, B. T., Thompson, S. H. & Goldstein, G. (1965) 'Fluorescent antibody staining. III. Preparation of fluorescein-isothiocyanate-labeled antibodies.' *J. Immunol.* **95**, 225-29.
- Yunis, E. J., Hilgard, H., Sjodin, K., Martinez, C. & Good, R. A. (1964) 'Immunological reconstitution of thymectomized mice by injections of isolated thymocytes.' *Nature (Lond.)* **201**, 784-86.
- Yunis, E. J., Hilgard, H. R., Martinez, C. & Good, R. A. (1965) 'Studies on immunologic reconstitution of thymectomized mice.' *J. exp. Med.* **121**, 607-32.

Accepted for publication June 10, 1966.

Requests for reprints should be addressed to: Morten Harboe, M.D.
Institute for Experimental Medical Research
Ullevål Hospital, Oslo 1, Norway